Lecture 14 **Anatomy** د. احمد فاضل

Triangles of the neck

ANTERIOR TRIANGLE

Borders of the anterior triangle:
●Posteriorly: Anterior border of the sternocleidomastoid
●Superiorly: Inferior border of the mandible
●Anteriorly: Midline of the neck
Using the hyoid as a keystone, the omohyoid and digastric muscles subdivide the anterior triangle into:
● Submental triangle
● Submandibular triangle
● Carotid triangle
● Muscular triangle
All of the triangles within the anterior triangle are paired except for the submental triangle, which spans the right and the left sides of the neck

1. SUBMENTAL TRIANGLE

Borders of the submental triangle:
●inferiorly: Body of hyoid
● laterally: Anterior digastric on right and left
● anteriorly: midline of the neck

Floor of the triangle is composed of the:
● Mylohyoid

Roof is made of the:
● Skin
● Superficial fascia with platysma
● Deep cervical fascia

CONTENTS OF THE SUBMENTAL TRIANGLE			
Artery	Vein	Nerve	Structures
	Anterior jugular		Submental lymph nodes

2. SUBMANDIBULAR TRIANGLE

Often called the digastric triangle

Borders of the submandibular triangle:
- superiorly: Inferior border of the mandible
- posteriorly: Posterior belly of digastric and stylohioyd muscle
- anteriorly: Anterior belly of digastric

Floor of the triangle is composed of the:
- Hyoglossus
- Mylohyoid
- Middle constrictor

Roof is made of the:
- Skin
- Superficial fascia with platysma
- Deep cervical fascia

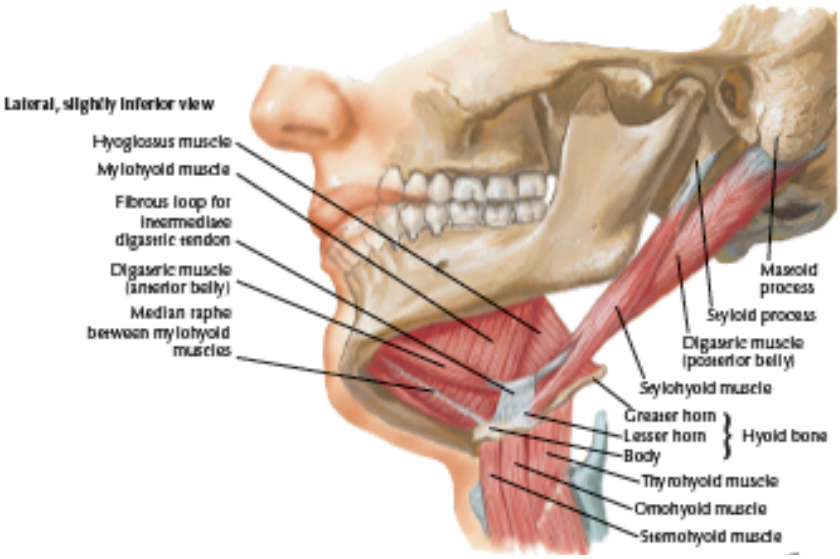

CONTENTS OF THE SUBMANDIBULAR TRIANGLE			
Arteries	**Veins**	**Nerves**	**Structures**
Facial Submental Lingual (small portion)	Facial Submental Lingual (small portion)	Mylohyoid Hypoglossal	Submandibular gland Submandibular lymph nodes Inferior portion of the parotid gland

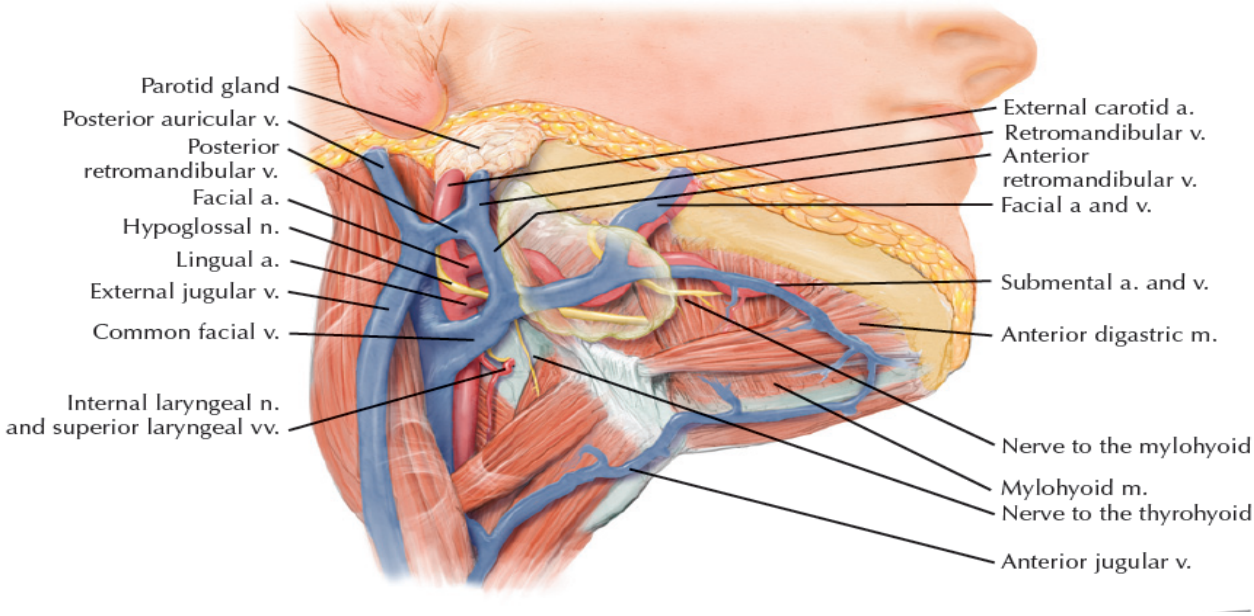

3. CAROTID TRIANGLE

Named because parts of all three carotid arteries are located within it

Borders of the carotid triangle:

- posterioly :Anterior border of the sternocleidomastoid
- superiorly: Posterior belly of digastric
- inferiorly: Superior belly of omohyoid

Floor of the triangle is composed of the:

- Hyoglossus
- Thyrohyoid
- Middle constrictor
- Inferior constrictor

Roof is made of the:

- Skin
- Superficial fascia with platysma
- Deep cervical fascia

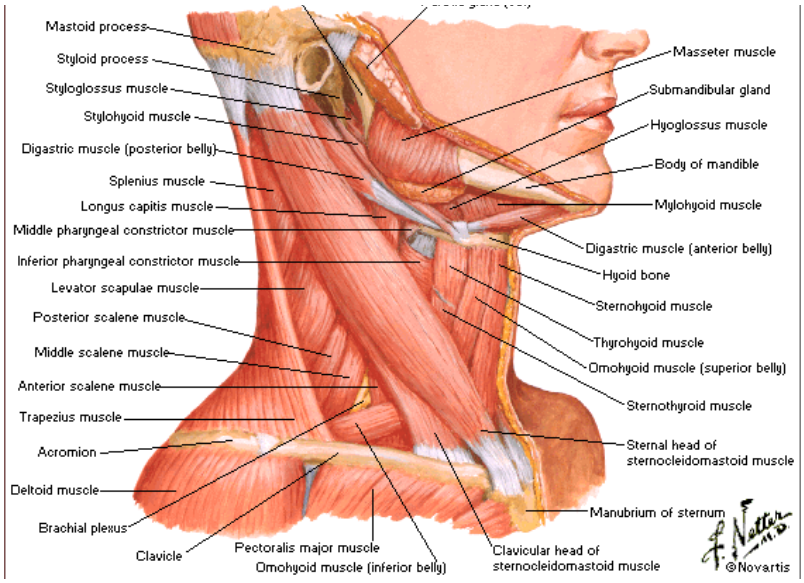

CONTENTS OF THE CAROTID TRIANGLE			
Arteries	**Veins**	**Nerves**	**Structures**

Common carotid (with carotid body)
• Internal carotid (with carotid sinus)
• External carotid
  • Superior thyroid (with superior laryngeal branch)
  • Lingual
  • Facial
  • Ascending pharyngeal
  • Occipital
	Internal jugular
	Common facial
	Lingual
	Superior thyroid
	Middle thyroid
		Vagus
		• External laryngeal
		• Internal laryngeal
		Spinal accessory (small portion)
		Hypoglossal
		Ansa cervicalis (superior limb)
		Sympathetic trunk
			Larynx (small portion)
			Thyroid (small portion)

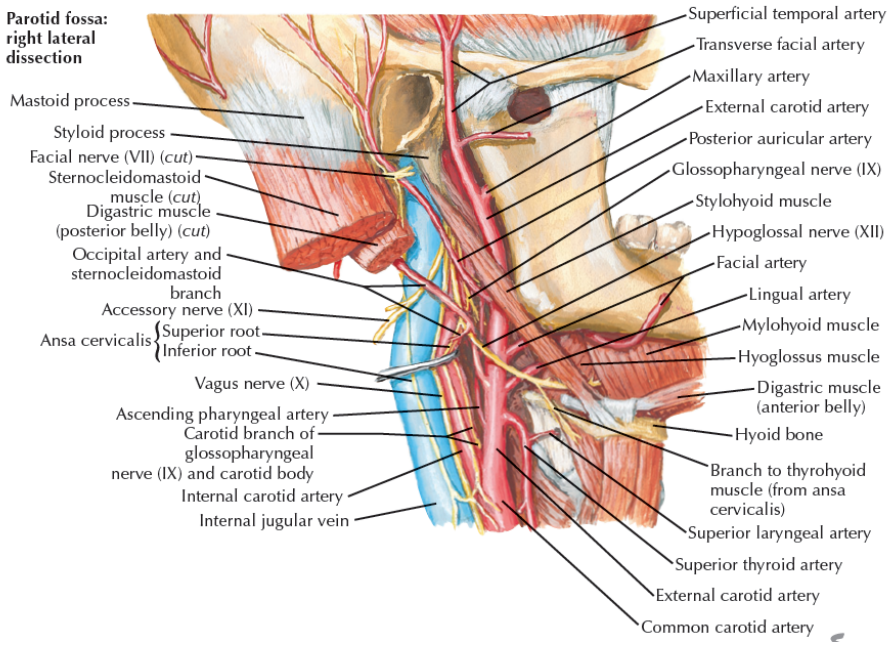

4. MUSCULAR TRIANGLE

Borders of the muscular triangle:

- Inferiorly: Anterior border of the sternocleidomastoid
- Superiorly: Superior belly of omohyoid
- Anteriorly: Midline

Floor of the triangle is composed of the:

- Sternohyoid
- Sternothyroid

Roof is made of the:

- Skin
- Superficial fascia with platysma
- Deep cervical fascia

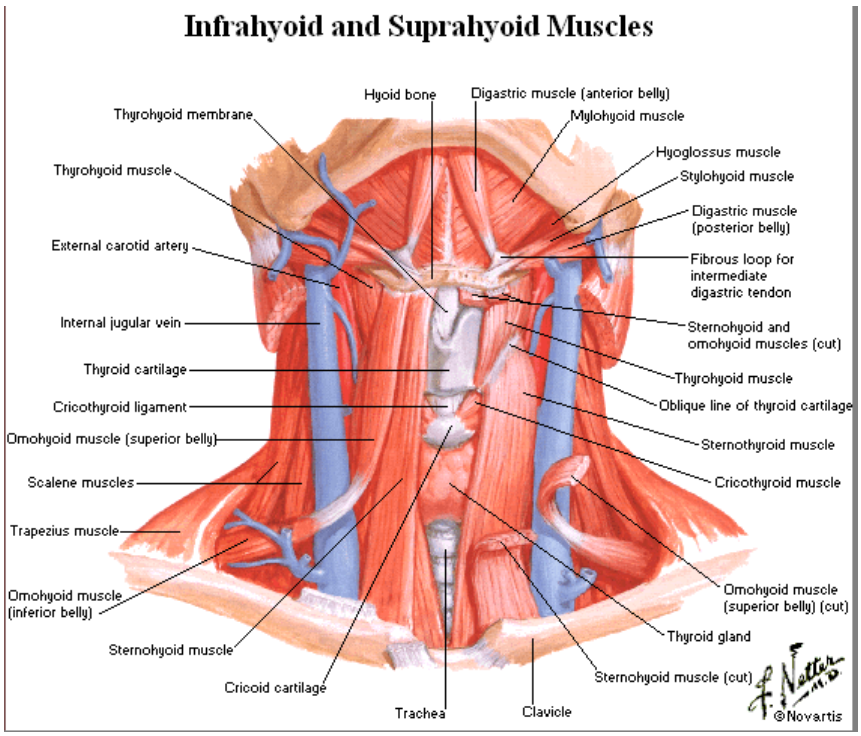

CONTENTS OF THE MUSCULAR TRIANGLE			
Artery	**Veins**	**Nerve**	**Structures**
Superior thyroid	Inferior thyroid Anterior jugular	Ansa cervicalis	Strap muscles: • Sternohyoid • Sternothyroid • Thyrohyoid Thyroid gland Parathyroid gland Larynx Trachea Esophagus

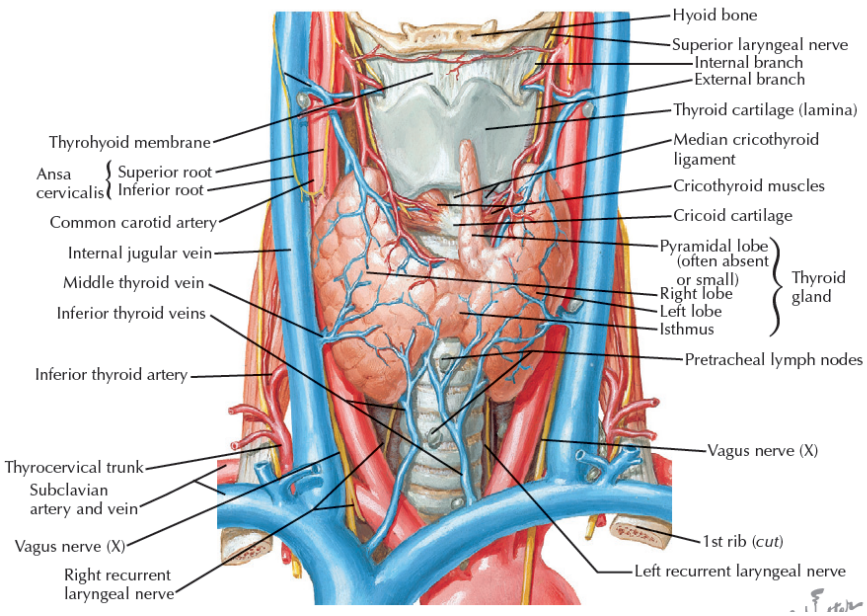

Posterior Triangle

Borders of the posterior triangle:

- anteriorly: Posterior border of the sternocleidomastoid
- inferiorly: Middle third of the clavicle
- posteriorly: Anterior border of the trapezius

Is subdivided into 2 triangles by the omohyoid:
- Omoclavicular (also called the supraclavicular triangle)
- Occipital

Roof of the posterior triangle includes:
- Skin
- Superficial fascia with platysma
- Superficial (investing) layer of deep cervical fascia

Floor of the posterior triangle includes*:
- Semispinalis capitis
- Splenius capitis
- Levator scapulae
- Posterior scalene
- Middle scalene
- Anterior scalene

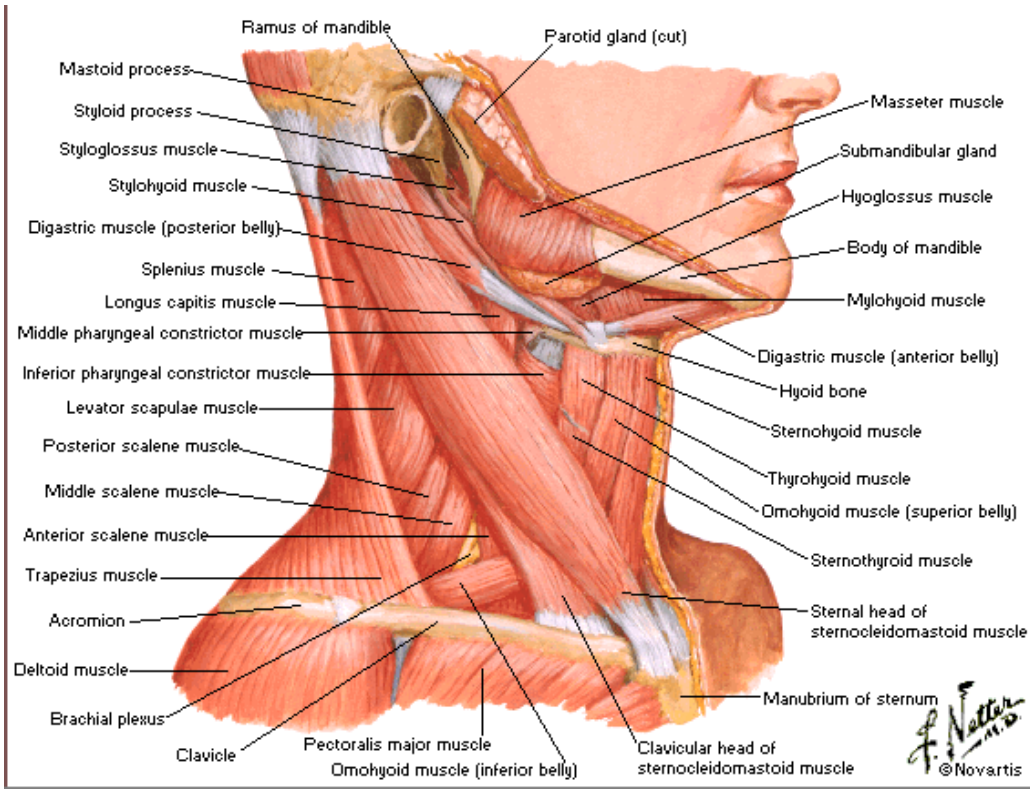
Ramus of mandible
Parotid gland (cut)
Mastoid process
Styloid process
Styloglossus muscle
Stylohyoid muscle
Digastric muscle (posterior belly)
Splenius muscle
Longus capitis muscle
Middle pharyngeal constrictor muscle
Inferior pharyngeal constrictor muscle
Levator scapulae muscle
Posterior scalene muscle
Middle scalene muscle
Anterior scalene muscle
Trapezius muscle
Acromion
Deltoid muscle
Brachial plexus
Clavicle
Pectoralis major muscle
Omohyoid muscle (inferior belly)
Clavicular head of sternocleidomastoid muscle
Manubrium of sternum
Sternal head of sternocleidomastoid muscle
Sternothyroid muscle
Omohyoid muscle (superior belly)
Thyrohyoid muscle
Sternohyoid muscle
Hyoid bone
Digastric muscle (anterior belly)
Mylohyoid muscle
Body of mandible
Hyoglossus muscle
Submandibular gland
Masseter muscle
F. Netter M.D.
©Novartis

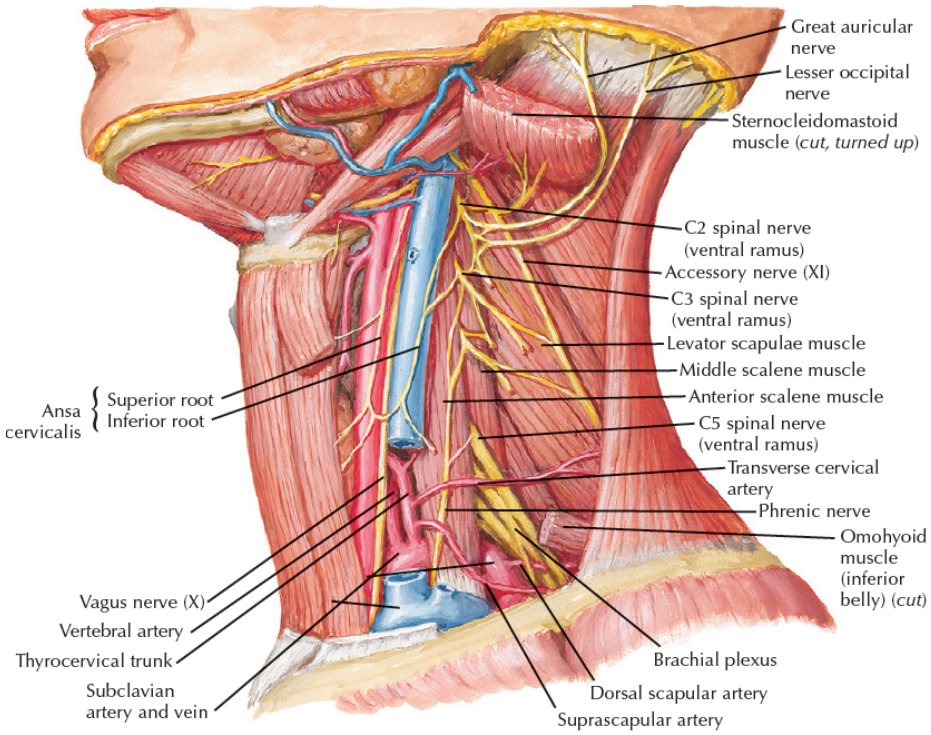
Great auricular nerve
Lesser occipital nerve
Sternocleidomastoid muscle (cut, turned up)
C2 spinal nerve (ventral ramus)
Accessory nerve (XI)
C3 spinal nerve (ventral ramus)
Levator scapulae muscle
Middle scalene muscle
Anterior scalene muscle
C5 spinal nerve (ventral ramus)
Transverse cervical artery
Phrenic nerve
Omohyoid muscle (inferior belly) (cut)
Ansa cervicalis
Superior root
Inferior root
Vagus nerve (X)
Vertebral artery
Thyrocervical trunk
Subclavian artery and vein
Brachial plexus
Dorsal scapular artery
Suprascapular artery

Thyroid Gland

Location and Description

The thyroid gland consists of right and left lobes connected by a narrow isthmus . It is a vascular organ surrounded by a sheath derived from the pretracheal layer of deep fascia. The sheath attaches the gland to the larynx and the trachea.

Each lobe is pear shaped, with its apex being directed upward as far as the oblique line on the lamina of the thyroid cartilage; its base lies below at the level of the fourth or fifth tracheal ring.

The **isthmus** extends across the midline in front of the second, third, and fourth tracheal rings. A **pyramidal lobe** is often present, and it projects upward from the isthmus, usually to the left of the midline. A fibrous or muscular band frequently connects the pyramidal lobe to the hyoid bone; if it is muscular, it is referred to as the **levator glandulae thyroideae**.

Relations of the Lobes

Anterolaterally: The sternothyroid, the superior belly of the omohyoid, the sternohyoid, and the anterior border of the sternocleidomastoid

Posterolaterally: The carotid sheath with the common carotid artery, the internal jugular vein, and the vagus nerve

Medially: The larynx, the trachea, the pharynx, and the esophagus. Associated with these structures are the cricothyroid muscle and its nerve supply, the external laryngeal nerve. In the groove between the esophagus and the trachea is the recurrent laryngeal nerve.

The rounded posterior border of each lobe is related posteriorly to the superior and inferior parathyroid glands and the anastomosis between the superior and inferior thyroid arteries.

Relations of the Isthmus

Anteriorly: The sternothyroids, sternohyoids, anterior jugular veins, fascia, and skin

Posteriorly: The second, third, and fourth rings of the trachea

The terminal branches of the superior thyroid arteries anastomose along its upper border.

Blood Supply

The **arteries** to the thyroid gland are the superior thyroid artery, the inferior thyroid artery, and sometimes the thyroidea ima. The arteries anastomose profusely with one another over the surface of the gland.

1. The **superior thyroid artery,** a branch of the external carotid artery, descends to the upper pole of each lobe, accompanied by the **external laryngeal nerve**

2. The **inferior thyroid artery,** a branch of the thyrocervical trunk, ascends behind the gland to the level of the cricoid cartilage. It then turns medially and

downward to reach the posterior border of the gland. The **recurrent laryngeal nerve** crosses either in front of or behind the artery, or it may pass between its branches.

3. The **thyroidea ima,** if present, may arise from the brachiocephalic artery or the arch of the aorta. It ascends in front of the trachea to the isthmus.

The **veins** from the thyroid gland are

1. The superior thyroid, which drains into the internal jugular vein;
2. The middle thyroid, which drains into the internal jugular vein;
3. The inferior thyroid veins of the two sides anastomose with one another as they descend in **front of the trachea.** They drain into the left brachiocephalic vein in the thorax.

Lymph Drainage

The lymph from the thyroid gland drains mainly laterally into the deep cervical lymph nodes. A few lymph vessels descend to the paratracheal nodes.

Nerve Supply

Superior, middle, and inferior cervical sympathetic ganglia

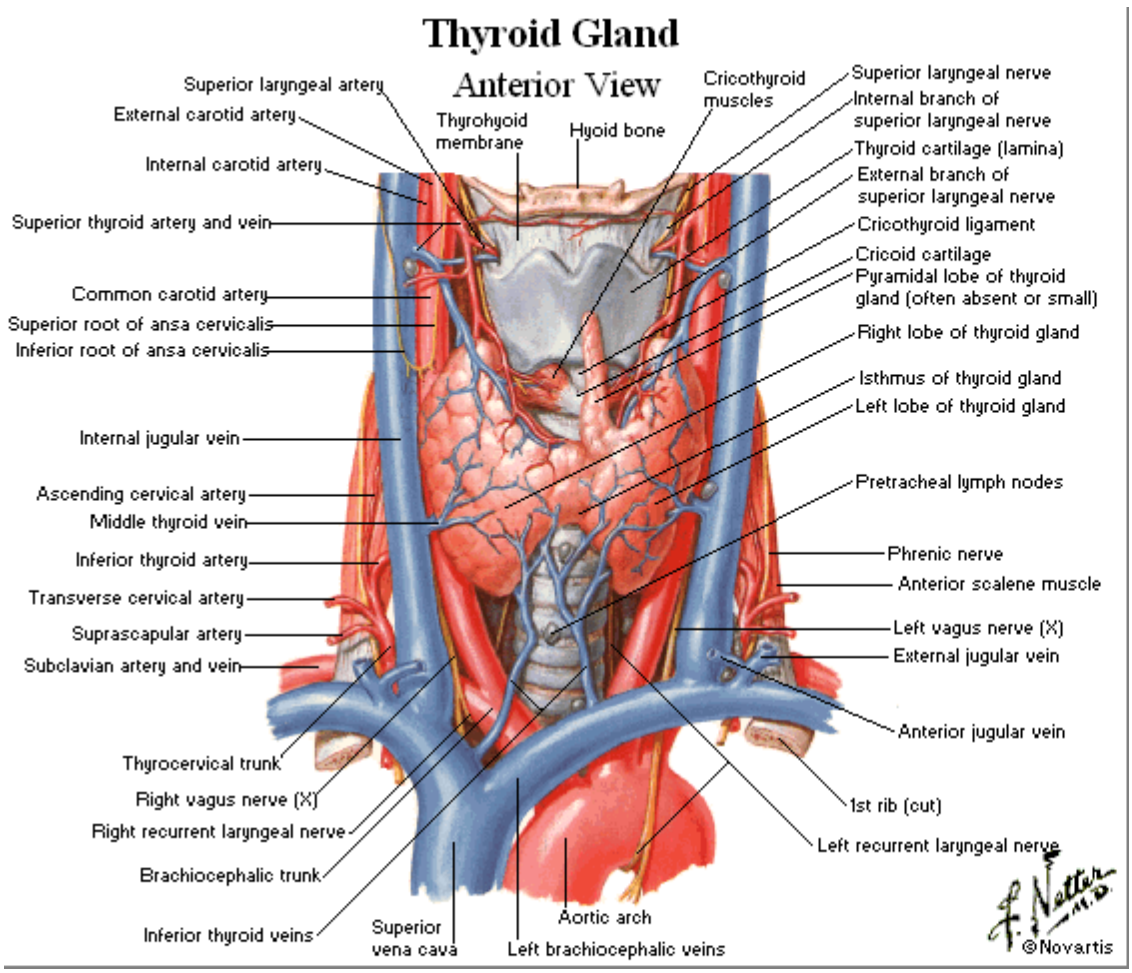

Functions of the Thyroid Gland

The thyroid hormones, thyroxine and triiodothyronine, increase the metabolic activity of most cells in the body. The parafollicular cells produce the hormone thyrocalcitonin, which lowers the level of blood calcium.

Parathyroid Glands

Location and Description

The parathyroid glands are ovoid bodies measuring about 6 mm long in their greatest diameter. They are four in number and are closely related to the posterior border of the thyroid gland, lying within its fascial capsule.

The **two superior parathyroid glands** are the more constant in position and lie at the level of the middle of the posterior border of the thyroid gland.

The **two inferior parathyroid glands** usually lie close to the inferior poles of the thyroid gland. They may lie within the fascial sheath, embedded in the thyroid substance, or outside the fascial sheath. Sometimes, they are found some distance caudal to the thyroid gland, in association with the inferior thyroid veins, or they may even reside in the superior mediastinum in the thorax.

Blood Supply

The arterial supply to the parathyroid glands is from the superior and inferior thyroid arteries. The venous drainage is into the superior, middle, and inferior thyroid veins.

Lymph Drainage

Deep cervical and paratracheal lymph nodes.

Nerve Supply

Superior or middle cervical sympathetic ganglia.

Functions of the Parathyroid Glands

The chief cells produce the **parathyroid hormone,** which stimulates osteoclastic activity in bones, thus mobilizing the bone calcium and increasing the calcium levels in the blood. The parathyroid hormone also stimulates the absorption of dietary calcium from the small intestine and the reabsorption of calcium in the proximal convoluted tubules of the kidney. It also strongly diminishes the reabsorption of phosphate in the proximal convoluted tubules of the kidney. The secretion of the parathyroid hormone is controlled by the calcium levels in the blood.

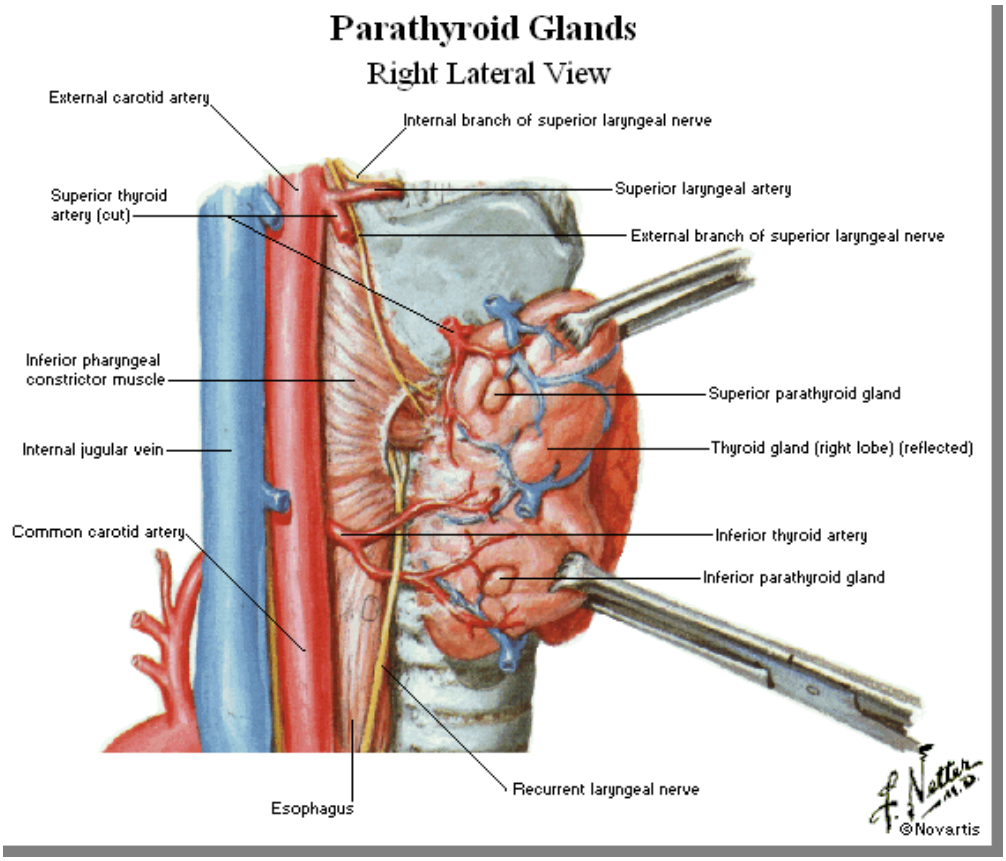
Parathyroid Glands
Right Lateral View
External carotid artery
Internal branch of superior laryngeal nerve
Superior thyroid artery (cut)
Superior laryngeal artery
External branch of superior laryngeal nerve
Inferior pharyngeal constrictor muscle
Superior parathyroid gland
Internal jugular vein
Thyroid gland (right lobe) (reflected)
Common carotid artery
Inferior thyroid artery
Inferior parathyroid gland
Recurrent laryngeal nerve
Esophagus
F. Netter M.D.
©Novartis